



**ACADEMICIA**  
**An International**  
**Multidisciplinary**  
**Research Journal**  
 (Double Blind Refereed & Peer Reviewed Journal)



**DOI: 10.5958/2249-7137.2021.02070.X**

## ATYPICAL LOCATION OF TERATOMA IN CHILDREN FEATURES OF DIAGNOSIS AND TREATMENT

**Karimova Zevara Khadjibaevna\***; **Kurambaev Yahshimurat Bekchanovich\*\***;  
**Latipov Djavdat Akhmedovich\*\*\***; **Yakubova Mariam\*\*\*\***;  
**Sagdullaev Narzulla Norkeldievich\*\*\*\*\***

<sup>1,5</sup>Termez branch of the Tashkent Medical Academy,  
UZBEKISTAN

### ABSTRACT

*The article presents teratomas of rare localization in children according to the authors' observations from 2003 to 2015. During this period, 69 children were examined and treated at the Department of Hospital Pediatric Surgery of Tashkent Pediatric medical institute. Sacro-coccygeal teratomas were detected in 52 (75.4%), teratomas of rare localization in 17 (24.6%) children aged from 1 month to 14 years old. Among the observed children the girls were 42 (60.9%), the boys - 27 (39.1%). For diagnostic purposes, in addition to generally accepted clinical and laboratory studies, the children underwent ultrasound, MSCT, rectoromanoscopy, irrigology, excretory urography examinations. Considering that the teratomas are mixed tumors of a complex structure, capable of malignancy, the details of the clinical course, diagnosis and results of treatment of children with the presented pathology were studied in this research. Based on the analysis of the described observations, the authors came to the conclusion that there is a need for an early surgical intervention, which has no alternative in treating children with teratomas, regardless of their type, localization and extent of the process, in order to avoid the risk of developing severe complications.*

**KEYWORDS:** *Teratomas, Malignancy, Localization, Children*

### INTRODUCTION

Teratomas are mixed tumors of a complex structure. Tissues arising from 2-3 germinal leaves can be found in them. Their presence is unusual in the organs and anatomical areas in which the tumor develops. It is known that the occurrence of teratoma is a consequence of a violation of the

embryo morphogenesis. Teratoid tumors constitute 5.9% of tumors in children, and 22.4% of cases in newborns and infants. The frequency is 1 in 35,000 live births [1, 2, 20]. According to the localization, mature or benign teratomas and immature (malignant) or teratoblastomas of gonadal and extragonadal area, are distinguished [1, 3,4,5,6,8,19]. The frequency of malignancy of the tumor is directly proportional to the age. The risk of malignancy in newborns does not exceed 5%, in children under 1 year old it constitutes more than 60%, in children over 1 year old — 75%. Malignant teratomas (teratoblastomas) are multicomponent formations, the tissues of which reach different degrees of differentiation with the presence of malignant elements. The morphology of teratomas is extremely diverse and fully justifies its name "miraculous tumors." The presence of immature embryonic tissues in them serves as a basis for treating them as tumors [2,3,6,7,9]. According to their course, they can be regarded as a malformation. Associated anomalies are observed in 20% of cases. Teratoid tumors are found in various body cavities, in almost any organ and body tissues [3, 4, 5,8,14]. The diagnosis of extracavitary teratomas is not difficult. Such formations can be established before the birth of the child. In some cases, their removal is recommended in the antenatal period [4,10,11]. Diagnostics and tactics of treatment of germ cell tumors with rare localization teratomas are not well understood yet.

The aim of the work is to analyze the clinical course, diagnosis and the results of surgical treatment of children with teratomas of rare localization based on clinic materials.

### Materials and Methods

From 2003 to 2015, 69 children with teratomas of various localization were treated at the Department of Hospital Pediatric Surgery of Tashkent Pediatric medical institute: sacro-coccygeal teratomas (SCT) - 52 (75.4%); teratomas of rare localization - 17 (24.6%). The age of the patients was from 1 month to 14 years old. There were 42 girls (60.9%) and 27 boys (39.1%). In the diagnosis, in addition to the generally accepted clinical and laboratory methods, ultrasound (US), multispiral computed tomography (MSCT), rectoromanoscopy, irrigology and excretory urography were used.

### RESULTS AND DISCUSSION

The size, shape and localization of teratomas were noted in children of different age groups (Table 1).

**TABLE 1 THE DISTRIBUTION OF PATIENTS BY AGE AND LOCALIZATION OF TERATOMAS (N = 69)**

Patients' age		1-3 months	4-6 months	7-12 months	1-4 years	> 4 years	Total :
Sacro-coccygeal	External type	5	6	4	—	—	15 (21,8%)
	Internal type	—	5	6	—	—	11 (15,9%)
	Mixed type	7	11	8	—	—	26

							(37,7%)
Teratomas of abdominal cavity	Abdomen	–	–	–	2	–	2 (2,9%)
	Mesentery of the intestine	–	1	2		–	3 (4,3%)
Genital teratomas	Ovary	–	1	–	1	2	4 (5,8%)
	Testicle	–	–	–	2	1	3 (4,3%)
Chest teratomas		–	–	2	2	–	4 (5,8%)
Retroperitoneal teratomas		–	–	–	–	1	1 (1,5%)
Total:		12 (17,4%)	24 (34,8%)	22 (31,9%)	7 (10,1%)	4 (5,8%)	69 (100%)

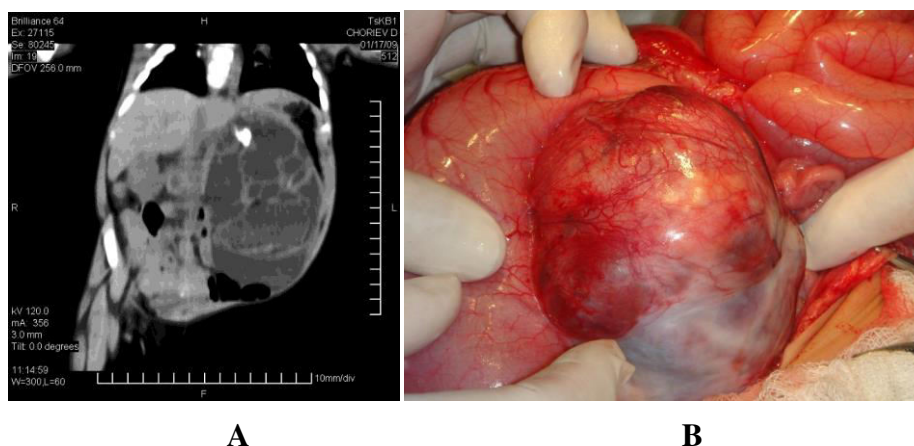
As can be seen from the table, sacro-coccygeal teratomas (SCT) of various localization and depth, are most often observed. In other areas and organs of the body, teratomas are rarely observed, which correlates with the literature data. The internal type of SCT localization - presacral teratoma - is also considered as a rare pathology variant by some authors.

As a rule, teratomas of external localizations are found from birth. Sometimes formations reach a very large size and make the childbirth difficult. Methods of diagnosis of teratoid tumors depend on their localization. Screening and informative diagnostic method is ultrasound. During the ultrasound, the location, size, structure of the formation and belonging of the organ are determined [12,16,17,18]. As an additional method in the diagnosis X-ray and CT studies, allowing to find out the connection of the tumor with the surrounding tissues and associated malformations, can be used. Currently, CT has practically become the leading diagnostic method for teratomas of any localization. Based on CT examination data, in 22 (31.9%) of 69 patients were found to have associated developmental defects: coccyx hypoplasia - 10 (14.5%); connection of teratoma with spinal hernia - 7 (10.1%); uretero-hydronephrosis - 2 (2.9%); anomalies of the development of the ribs - 2 (2.9%); incomplete doubling of the kidneys - 1 (1.5%).

The clinical manifestations of teratomas are diverse and are largely determined by their localization. Abdominal teratoma localization was noted in 5 (7.2%) cases of our observations. According to the literature, gastric teratoma is rare and accounts for about 1% of tumors of this

localization. Gastric teratomas in newborns and infants are often observed among boys and have a low propensity for malignancy [1,4,5,12,18,20]. Teratoma can be detected in a child in any organ or in the abdominal cavity in the form of formation of various sizes. The small size of the tumor remains unnoticed for a long time due to the absence of pain and symptoms of obstruction. With the increasing of the teratoma, vomiting, bouts of pain, constipation periodically appear. A careful examination of the abdomen, in such cases, reveals its asymmetry to some extent due to bulging on the side of education. Palpation is determined sedentary painless education with smooth or uneven contours. In our observations, stomach teratomas were detected in 2 children aged 3 years, which constituted up to 2.9% of the patients with teratoid tumors. The disease was manifested by the palpable formation in the epigastric region, the symptoms of partial high intestinal obstruction and a body mass deficit of up to 20-30%.

Contrast studies of the gastrointestinal tract showed partial obstruction on the stomach level; with ultrasound and MSCT, an increase in the organ was established due to the intimately adjacent formation of a heterogeneous structure (Fig.1).

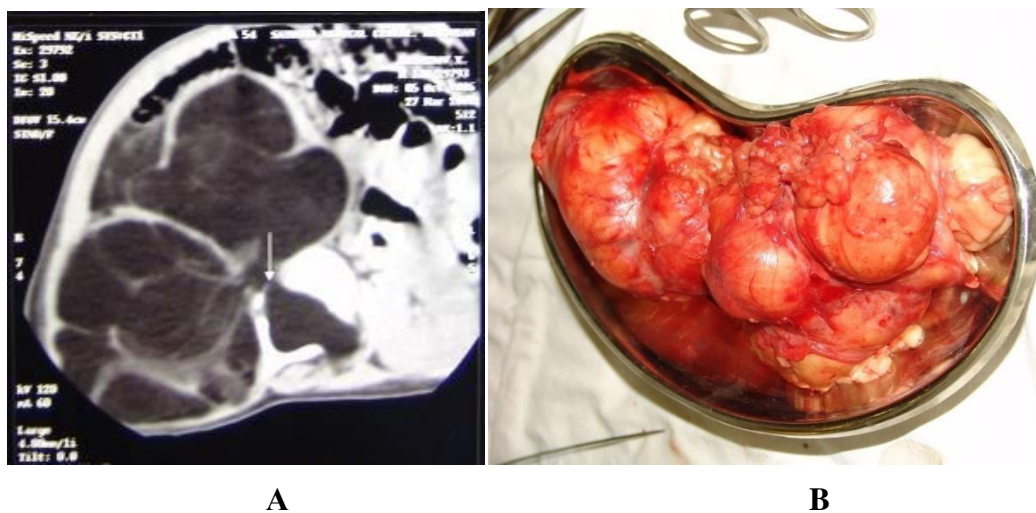


**Fig.1 Stomach teratoma: A) CT scan - heterogeneous formation in the projection of the stomach; B) the view of tumor during surgery.**

Patients are operated with the suspect of doubling of the stomach. During the operation, it was possible to completely separate the formation from the body of the stomach that was situated along the greater curvature. The macroscopic structure was heterogeneous, had solid cystic character with mucus-like contents and heterogeneous inclusions (hair and cartilage plates) that made it possible to regard the pathology as teratoma of the stomach. The diagnosis was confirmed by histomorphological examination of the removed tumor. The postoperative period was uneventful. Patients were discharged in satisfactory condition.

Teratoid tumors of the mesentery of the large intestine were diagnosed in 3 children. The patients were operated on with the diagnosis of “abdominal tumor”, since “palpable tumor syndrome” in the abdominal cavity was revealed via the main clinical manifestation and auxiliary examinations. The formation was located along the mesenteric edge of the colon within the ascending and descending colon (Fig.2-A). In 2 patients, the formation was spread in the mesentery and consisted of numerous nodes of different size with solid structure and heterogeneous content, and enveloped in a capsule (Fig.2-B). It was separated from the adjacent

section of the colon. In one child, the formation of the structure mentioned above, engulfed over 10 cm of the descending colon in the form of a coupling with intimate soldering to the wall. In this case, along with the removal of the tumor-like formation, the resection of the corresponding section of the large intestine with the imposition of an end-to-end anastomosis was required. The histological findings in these observations became the basis for the diagnosis of teratoma of the specified localization.

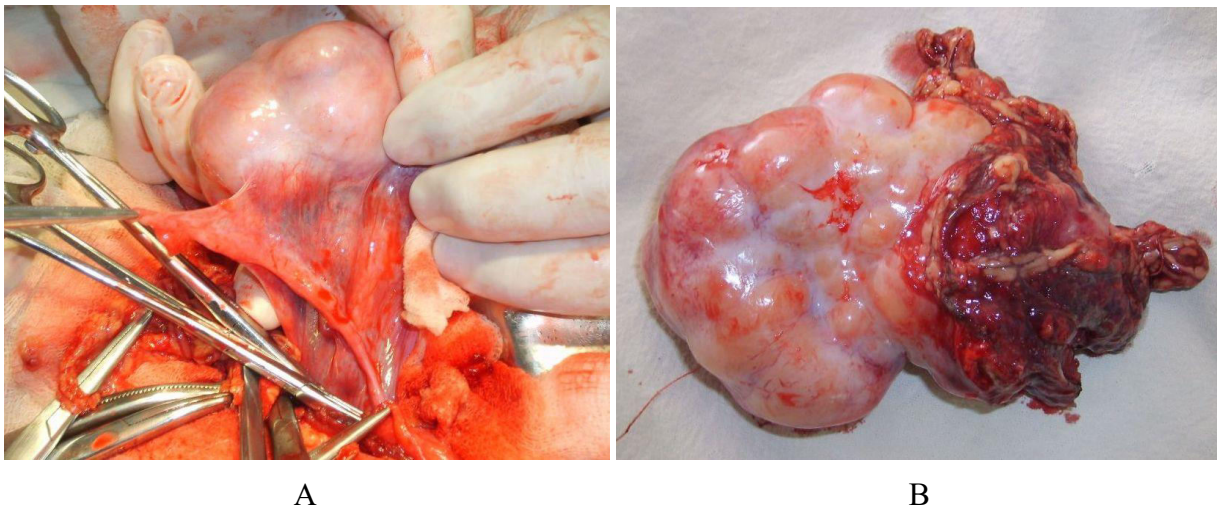


**Fig.2 Teratoid tumor of the mesentery of the large intestine: A) CT scan of the abdominal cavity - a giant formation of heterogeneous structure; B) macropreparate of the removed tumor.**

Of the 52 patients with SCT, 11 (21.1%) were diagnosed with an internal type of tumor localization. 11 children with presacral localization of the SCT were hospitalized with complications of the disease in the form of a difficult act of defecation and/or urination, abdominal pain. Two had the symptoms of general intoxication: pale skin, weight loss, physical development lag, vomiting, fever. A finger study of the rectum revealed a presacally located tumor-like mass. These ultrasound and MSCT allowed to establish the correct diagnosis. Impaired pelvic function and dysuria in these patients were due to compression of the rectum and ureter by a tumor-like formation; intoxication phenomena in two patients - due to the malignancy. Complications are usually manifested by bright symptoms and deterioration of the child's general condition. By the time of birth, a tumor can squeeze or displace the rectum so much that from the first days of life a child has intestinal obstruction. When a bladder is pressed, the complication is manifested by urinary retention; the urine is separated by drops, the bladder is stretched, the child is worried when urinating, and retches. Catheterization is difficult. The compression of a rectum or urethra by a tumor in some patients was observed at the age of 2-3 months; in one child - at an older age. The compression of the ureter in two patients led to the development of secondary ureterohydronephrosis.

Gonadal teratomas in 7 children were presented in the form of ovarian teratomas in girls and testicular teratomas in boys. Four girls were observed with ovarian teratoma. The main clinical signs were the presence of volumetric formation and abdominal pain. Two girls were hospitalized in an emergency due to increased pain syndrome with irradiation to the perineum,

the appearance of a delayed stool and painful urination. An objective examination drew attention to the paleness of the skin, increased heart rate, massively spread pain and active muscle tension during palpation of the abdomen. In 2 cases, the main symptom was palpation of the tumor-like formation without pain and disorders of defecation and diuresis. The data of clinical examination and auxiliary examination methods before the operation found twisted ovarian cyst in 2, and mesentery cyst in 1 patient. In 1 child, a possible pathological process associated with ovarian tumor, was suggested. After careful examination, all patients were operated on. The final volume of surgery, as a rule, was determined during the operation. In two girls, teratoma was represented by a unilateral tumor formation sized 7x8x6cm having cystic and solid structures and heterogeneous inclusions, covered with a single thick sheath that had grown into the ovarian tissue, containing more than 12 different sizes. In this case, the operation was completed by removing the tumor and ovarian tissue (Fig.3-A). In the second girl, the tumor capsule adhered to the ovarian tissue without macroscopic changes. The tumor was accepted as benign. The volume of operation was sparing, and limited to the removal of the tumor with preservation of the ovarian tissue. In two girls, the formation consisted of multi-chamber nodes represented by solid tissue structures and many components of heterogeneous inclusions with diffuse growth of the capsule in the infiltrated ovarian tissue. The surface of the tumor had a hilly character, the size exceeding 12 cm in diameter. The changes are regarded as ovarian teratoblastoma without spreading to the second ovary and lymph nodes. The operation is completed by removing the tumor and the ovary as a single unit (Fig.3-B).

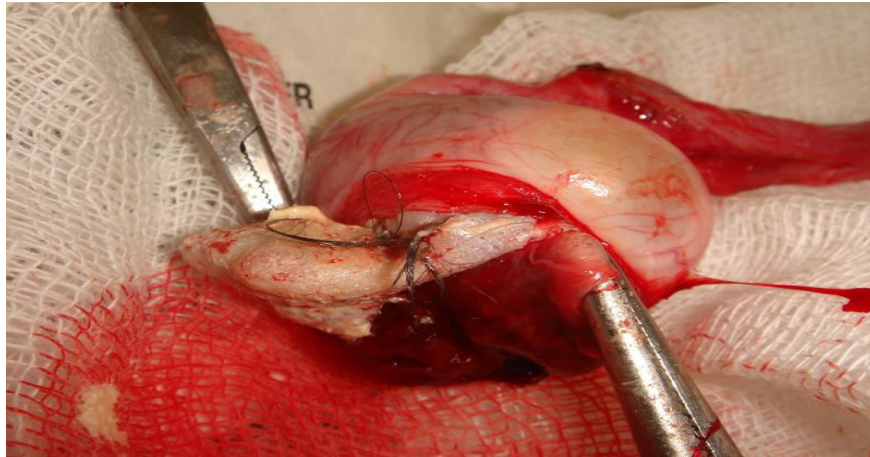


**Fig.3 Teratoma of the ovary: a) the view during operation, b) macropreparate of the removed tumor.**

Testicular teratomas are more common in children under the age of 2 years, and are often detected from birth. Teratomas are benign as opposed to adults whose ovarian teratomas are malignant. The cases of malignant teratoma in boys 15-16 years of flat keratinizing epithelium, mucous glands, undifferentiated epithelial tissue have been described [1,2,4].

In our observations, teratoid tumors of the testes were detected in 3 children. In patients who were under observation due to the "tense dropsy," there was an increase and a sharp induration of one of the testicles. An ultrasound showed an increase in the affected testicles due to an

inhomogeneous solid structure. Orchofuniculectomy was performed. On the section of the macropreparation, heterogeneous tissue and hair were revealed (Fig.4).



**Fig.4 Testicular teratoma: adipose tissue and hair are determined in the incision**

Teratoid tumors of the chest were found in 4 patients: with the localization of the process in the anterior mediastinum - 3, and in the lung parenchyma - 1. All children were monitored and treated by pediatricians with suspected pneumonia, bronchitis, pleurisy. Like other benign tumors of the chest, teratoma is manifested by respiratory symptoms associated with compression of the respiratory tract. Most often it is noisy, sometimes stridor breath. Rapid breathing may be due to the compression of the pulmonary parenchyma by the formation of large sizes. In the early stages, the tumor may be asymptomatic in the form of tachypnea during exercise. In 2 patients, due to the significant size of the tumor, the asymmetry of the chest was clearly defined. In one child, chest teratoma was detected on a roentgen as a random finding. On X-ray the teratoma is characterized as a formation with fuzzy contours, containing calcifications or bone inclusions. CT scan is more informative for diagnosis (Fig.5).

Patients with chest teratomas underwent surgery. Three patients underwent the resection of the tumor from the anterior mediastinum; one patient from the lobe of the lung bearing teratoid formation. Patients were discharged from the hospital in a satisfactory condition. In a child who underwent a resection of the lung, metastases are found in other organs in six months after the operation. Three patients after the removal of teratomas from the mediastinum are under observation, and developing according to their age.

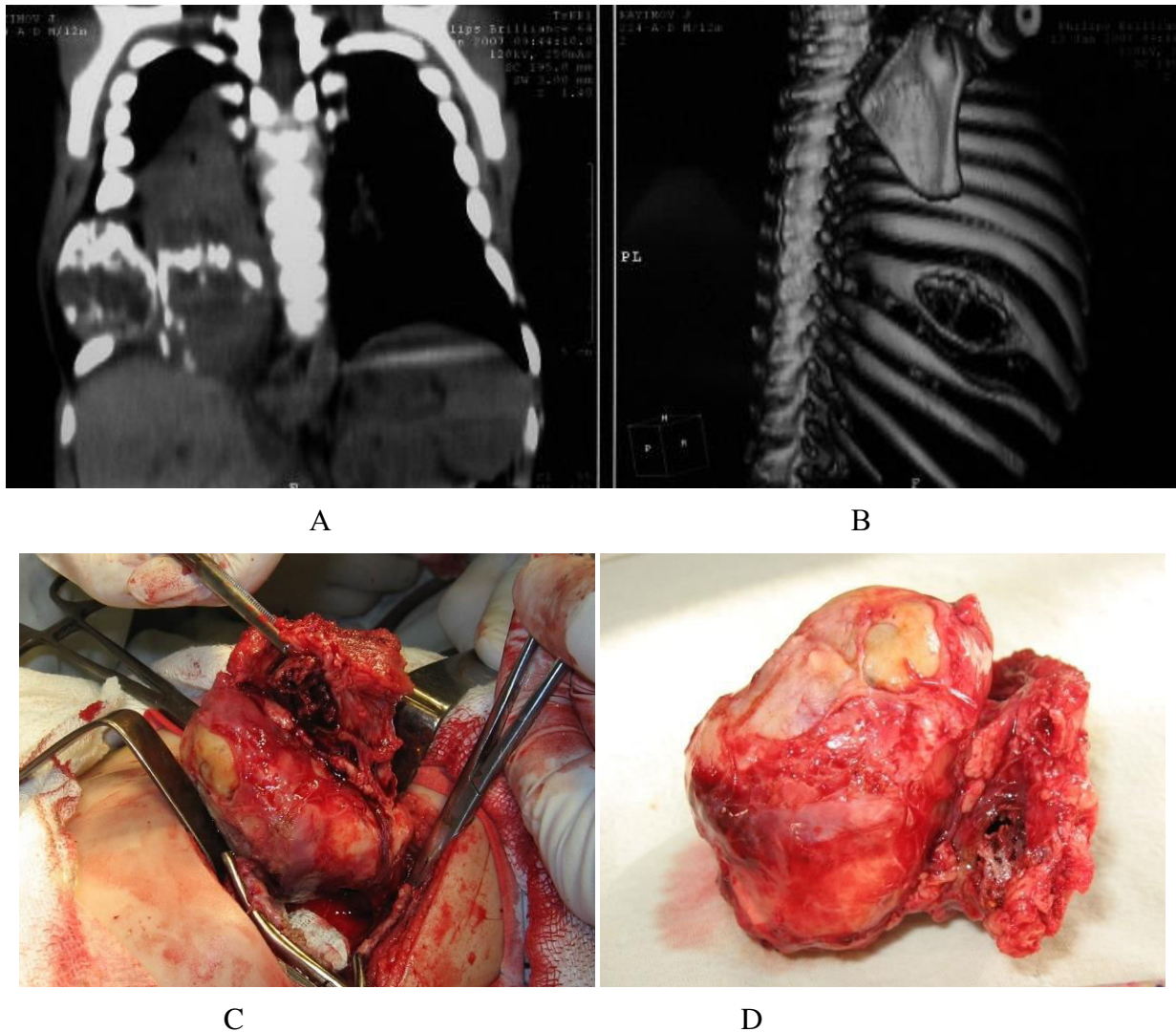
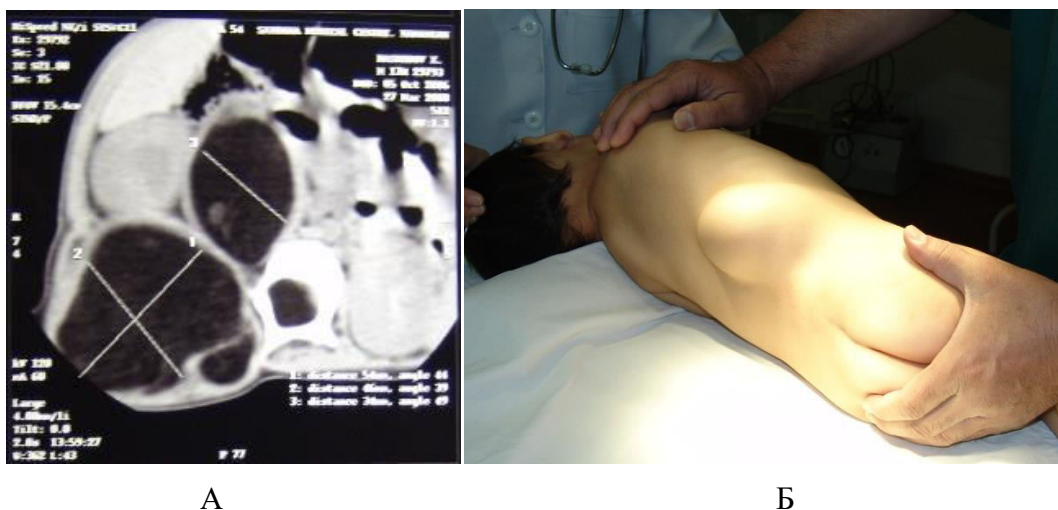


Fig.5 Teratoma of the right lung: inhomogeneous nodules with inclusions (A) are determined at CT; germination of the process to the 7th-8th ribs (B); view of the tumor during surgery (C); macropreparate (D)

In one patient, a teratoid tumor emanating from the retroperitoneal space was noted. Palpation revealed the formation of a dense consistency with a bumpy surface, limited mobility. CT scan showed a multi-chamber formation of a cystic and solid structure (Fig.6). The child was operated on. The bulk of the huge formation sized 15x17-20 cm consisted of adipose tissue in the form of nodes of various sizes, having a separate capsule, containing atheromatous nodes with hair and cartilage inclusions in some areas. The postoperative course is without complications. The patient is under observation.





**Fig. 6. Retroperitoneal teratoma: A) multi-chamber cystic formations are determined at CT; B) the view of the patient**

The need for the early surgical intervention in teratomas is undoubted and is supported by many authors. Like most other authors, we believe that teratomas, regardless of their localization, are subject to surgical removal as soon as possible after their detection. This prevents their excessive growth and the development of various complications. Indications for urgent surgical intervention are: compression of a rectum or urethra by a tumor, observed during internal localization of the SCT; suspected malignant degeneration. The rapid growth of the tumor, if it does not lead to squeezing of the organs of the perineum, should still be regarded as an indication for emergency surgery because of the risk of malignant degeneration.

In other locations, a rupture or dramatic thinning of the membranes during ulceration or necrosis of the skin, suppuration of individual cystic cavities, also serve as indications for the urgent operation. The nature and duration of preoperative preparation depend on the type of complications.

The postoperative period was uneventful in all patients. Our clinical observations show that if a tumor consists of benign mature tissue, then the removal of teratoma is the method of choice and provides good long-term results. With teratoblastomas, the long-term results of treatment were worse. In 2 (2.9%) patients the metastasis of the tumor and death were observed. Patients died within the first 4-6 months because of the tumor recurrence with generalization of the process and progressive tumor intoxication, anemia, cachexia. All patients recovered after surgery, complications were not observed. In all cases, the diagnosis of teratoma is confirmed by histomorphological examinations.

## CONCLUSIONS

Our clinical data correlate with the literature data that the peculiarity of teratomas in children is their benign course and rare metastasis into the nearby anatomical structures and organs. In most cases, teratomas have the character of multi-chamber cysts of various sizes or solid growths consisting of mature tissues, between which sometimes there are fields of solid growths of

undifferentiated embryonic character. Most teratomas are organoid, composed of structures resembling organs and various tissues, rudiments of limbs.

Benign teratomas tend to grow aggressively, but they do not grow into nearby anatomical structures, and malignant teratomas are characterized by aggressive growth and metastases into the nearby organs and other parts of the body. Cases of immature teratomas increase with age. This confirms the necessity of an early diagnosis and timely surgical intervention.

With teratomas of any localization, oncological alertness is a decisive factor in preventing their malignancy and other complications.

## BIBLIOGRAPHY

1. Ashcraft K.W., Holder T.M. Pediatric surgery. SPb: Raritet-M, 1999,400.
2. Durnov L.A., Polyakov V.E., Akhmedov B.P., Khakimov G.A. Guide to pediatric oncology. Tashkent. Abu Ali ibn Sino. 2001,500.
3. Klimenko VN Vneraradnye hemorrhagic tumors // Practical oncology. P. 63-68
4. Ergashev N.Sh., Diyarov N.A., Allaberganov I.K., Khurramov F.M. Teratomas of sacrococcygeal area in children. New day in Medicine. Tashkent. 2014;2:57-61.
5. Akinkuotu A.C., Coleman A., Shue E., Sheikh F., Sinjiro Hirose, Fooong-Yen Lim, Olutoye O.O Predictors of poor prognosis in prenataly diagnosed sacrococcygealteratoma: A multiinstitutional review. J. Pediatr. Surg. 2015; 50 (5): 771-4
6. Allen H.D., Moss and Adams' Heart Disease in Infants, Children, and Adolescent: Including the fetus and young Adult. Lippincot Williams and Wilkins; 2007.
7. Batt G.C., Nondan D., Sen A., Kanaujia P. Fever of Unknown Origin: A Case of Post Obstructive Pneumonia Complicating Mature Teratoma // Ann. Med. Health. Sci Res. 2013. Vol. 3. N 3. P. 461-463
8. Choi DJ, Wallace EC, Fraire AE, Baiyee D. Best cases from the AFIP: intrarenal teratoma. Radiographics. 2005;25(2):481-285.doi: 10.1016/j.jpedsurg.2006.03.019.
9. Goel A., Danaher L.,A. et al. Mediastinal teratoma // Radiopaedia.org.
10. Hedrick HL, Flake AW, Crombleholme TM et al. Sacrococcygeal teratoma: prenatal assessment, fetal intervention, and outcome. J Pediatr Surg. 2004;39:430-8.
11. Kim E, Bae T.S.,Kwon Y., Kim T.H., Chung K.W., Kim S.W. et al. Primary malignant teratoma with a primitive neuroektodermaltumor component in thyroid gland: a case report: J. Korean Med. Sci. 2007; 22 (3): 568-712007
12. Malogolowkin MN, Orteg J. Immature teratomas: identification of patients at risk for malignant recurrence. J. Nat. Cancer. Inst. 1989;81:870-874.
13. Mamedov Ad.A., Kirgizov I.V., Nelyubina O.V., Selitskaya A.B., Blinder Zh.A. A clinical case of teratomas of the oral cavity and oropharynx, combined with congenital cleft lip and palate. Detskayastomatologiya. 2012; (6): 8-10. (in Russia)

14. Morozov D.A., Pimenova E.S., Dvoryakovskiy I.V., Talalayev A.G. Thyreoidnyteratoma and newbonds. Detskayakhir. 2014; 18 (5): 33-6. (inRussia)
15. Neonatal Surgery. ( Neonatal'nayakhirurgiya). / Yu. Isakov, N.N. Volodin, A.V Geras'kin. Moskov: Dinastiya; 2011; 579-88. (in Russian)
16. Nzegwu MA, Aligbe JU, Akintomide GS, Akhigbe AO. Mature cystic renal teratoma in 25-year-old woman with ipsilateral hydronephrosis, urinary tract infection and spontaneous abortion. Eur J Cancer Care (Engl). 2007;16(3):300. doi: 10.1111/j.1365-2354.2006.00755.x.
17. Tapper D., Sawin R. Teratomas and Other Germ Cell Tumors. Pediatric Surgery. St.Louis. Baltimore-Boston: Mosby. 1998,447-459.
18. Tran K.M., Flake A.W., Kalawadia N.V. et all. Emergent excision of a prenatally diagnosed sacrococcygeal teratoma. Paediatr. Anaesth. 2008;12:28-35.
19. Yaqoab N. Ahmed Z. Jafri N, et al. Renal teratoma; a rare entity. J Pak Med Assoc. 2003;53(10):492-493
20. Yavuz A. Caken K. Alimoglu E, Akkaya B. Mature Cystic renal teratoma. Iran J Radiol. 2014;11(1):e11260. doi: 10.5812/iranjradiol.11260