


ACADEMICIA
**An International
 Multidisciplinary
 Research Journal**
 (Double Blind Refereed & Peer Reviewed Journal)



DOI: 10.5958/2249-7137.2021.01069.7

EVALUATION OF THE EFFECTIVENESS OF NEUROPROTECTIVE THERAPY ON RETINAL MORPHOMETRIC PARAMETERS IN PRIMARY OPEN-ANGLE GLAUCOMA

Karimova M.Kh*; Abulkasimova Kh.Kh**

*Republican Specialized center of eye microsurgery,
Tashkent, UZBEKISTAN

**Central Polyclinic Of JSC "Uzbekiston Temir Yullari",
Tashkent, UZBEKISTAN

ABSTRACT

Neuroprotective therapy refers to measures preventing damage to neurons in the retina and optic nerve. It should be carried out when the damage to the nervous tissue has not yet become irreversible [2, 3, 7, 8]. We examined 60 patients (120 eyes) with POAG I, II and III stages with the duration of glaucoma from 5 to 15 years. IOP was compensated by selective laser trabeculoplasty (SLT) surgery or local hypotensive therapy treated at the Central Polyclinic of JSC "UZBEKISTON TEMIR YULLARI", Tashkent. The patients were divided into 2 groups: group 1 (control) – 30 patients (60 eyes), who received only traditional medication therapy for glaucoma. Group 2 (main) consisted of 30 patients (60 eyes) who received OMK 2 in 1 drop 3 times a day for 1 month along with traditional medical treatment. All patients underwent the following ophthalmic examination methods with OCT, which was carried out on the device "3D OCT-1" by "Maestro 2". In this study, structural and functional progression in the control group was accompanied by a decrease in the thickness of the RNFL, GCC and the volume of the NRR. In the main group, these parameters were stable during the observation period or had a positive trend, which indicates the neuroretinoprotective effect of OMK 2. Thus, the use of OMK 2 allows improving the functional characteristics in patients with POAG. The positive effect is presumably associated with IOP control and neuroprotective properties of the medicine.

KEYWORDS: Primary Open-Angle Glaucoma, Neuroprotective Therapy, Optical Coherence Tomography, Citicoline (CDP-Choline).

INTRODUCTION

Primary open-angle glaucoma (POAG) is a chronic, progressive optical neuropathy in which morphological parameters in the optic nerve head and nerve fiber layer change in the form of retinal ganglion cell apoptosis and narrowing of the visual fields (European Guidelines for Glaucoma) in the absence of other eye diseases and congenital anomalies [6,8].

Apoptosis is a naturally regulated, ongoing, genetically programmed physiological process in which the death of single cells is observed, and then they are phagocytosed with the help of macrophages [2,3,15]. In pathological conditions, cells may die or as a result of necrosis – when a large amount of cells die under the influence of the violent actions of damaging (pathogenic) factors [4,8].

Neuroprotective therapy refers to measures preventing damage to neurons in the retina and optic nerve. It should be carried out when the damage to the nervous tissue has not yet become irreversible [2, 3, 7, 8].

To date, the choice of the optimal metabolic drug [5,15] for the treatment of glaucomatous optic neuropathy (GON), which should affect cell metabolism and ionic homeostasis, as well as have membrane stabilizing and antiapoptotic effects [8,9,10], remains relevant. A number of foreign studies show [11,13] a positive effect of citicoline (CDP-choline) on GON, by activating the biosynthesis of structural phospholipids of neuronal membranes, thereby increasing the synthesis of phosphatidylcholine and cerebral metabolism [14,18].

To ensure early detection of GON, as well as to assess the dynamics of glaucoma treatment, an incomparable role is played by one of the objective diagnostic methods of research – optical coherence tomography (OCT), which assesses the state of the optic nerve head (ONH) (optic nerve disc (OND)) and the retinal nerve fiber layer (RNFL)) [12,16].

This method makes it possible to estimate the magnitude and depth of the light signal, as well as to detect RNFL defects in the zones corresponding to changes in the visual fields using a beam of coherent infrared (IR) radiation with a wavelength of 820 nm, reflected from tissues of different optical properties, which determines the echo delay of the reflected light waves by measuring the intensity and depth of the signal [1,17]. When a light beam is focused on the target tissue, it is scattered and partially reflected from internal microstructures at different depths [19].

The diagnostic accuracy of measuring the thickness of the nerve fiber layer reaches more than 90% with a specificity of the study of 90%, therefore, the measurement of the thickness of the nerve fiber layer is mandatory when performing OCT for diagnostic purposes if glaucoma is suspected, as well as when observing patients with glaucoma. Theoretically, the thickness of the retinal nerve fiber layer, to a greater extent than the neuroretinal rim, reflects the state of the ganglion cells, since the volume of the latter, in addition to the nerve fibers, is largely filled by connective tissue and glial cells [1,19].

Objective

To evaluate the effectiveness of citicoline on optic nerve (ON) morphometric parameters in POAG with a stabilized level of intraocular pressure (IOP) using the OCT method.

MATERIALS AND METHODS

We examined 60 patients (120 eyes) with POAG I, II and III stages with the duration of glaucoma from 5 to 15 years. IOP was compensated by selective laser trabeculoplasty (SLT) surgery or local hypotensive therapy treated at the Central Polyclinic of JSC "UZBEKISTON TEMIR YULLARI", Tashkent.

The age of the patients ranged from 40 to 85 years. As the stage of the disease increased (stages II and III), the patients of more advanced age (over 60 years) were more frequent. The average age of the patients was 69.7 ± 5.3 years.

Figure 1: Distribution of patients with POAG by age

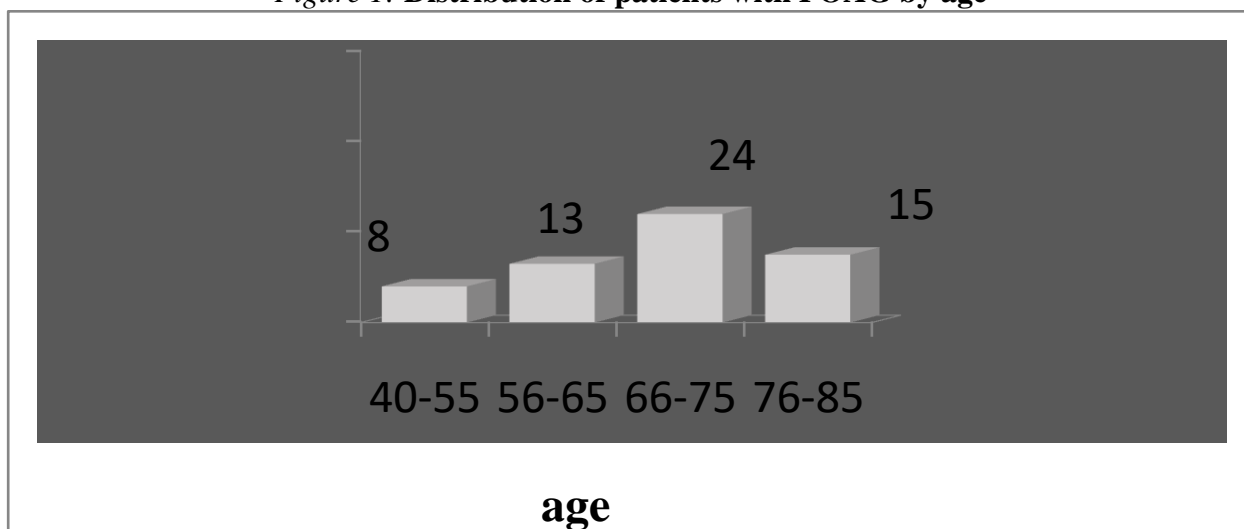
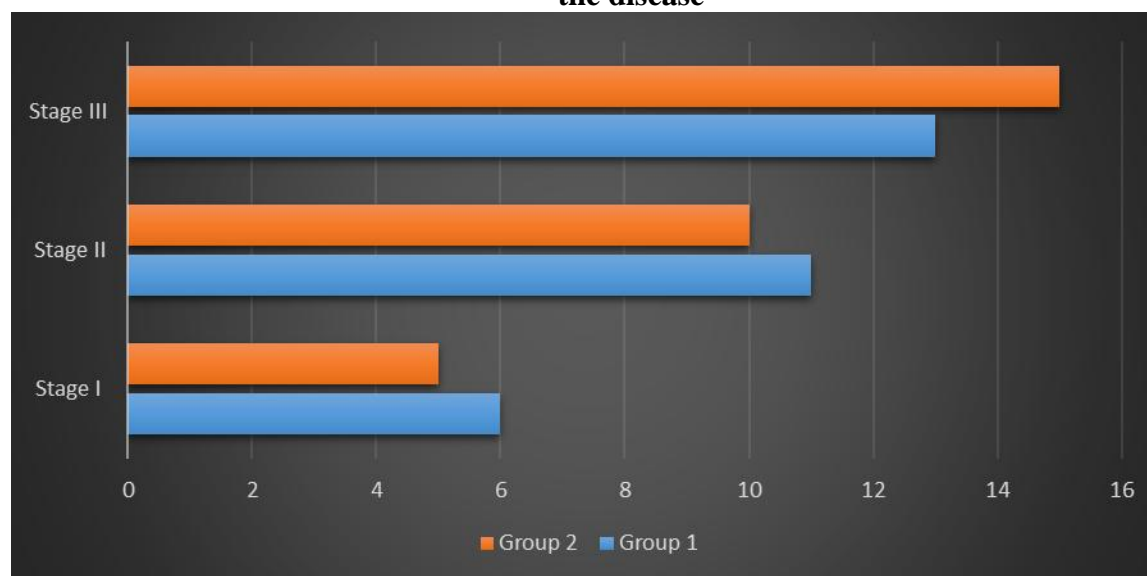


Figure 2: Distribution of patients with POAG in the study groups depending on the stage of the disease



The patients were divided into 2 groups depending on the type of treatment: group 1 (control) – 30 patients (60 eyes), who received only traditional medication therapy for glaucoma in a day hospital: 1% emoxipin solution at a dose of 0.5 ml 10 days (parabulbarly); 10% solution of piracetam at a dose of 5.0 ml (intravenously); 5% solution of pyridoxine hydrochloride at a dose of 1.0 ml, 5% solution of ascorbic acid at a dose of 2.0 ml intramuscularly for 10 days; cyanocobalamin 100 mg/day (intramuscularly), and cavinton 1 tab. 3 times a day, aevit 1 dragee 3 times a day for 1 month.

Group 2 (main) consisted of 30 patients (60 eyes) who received OMK 2 in 1 drop 3 times a day for 1 month along with traditional medical treatment. All patients underwent the following ophthalmic examination methods: visiometry with correction, perimetry, biomicroscopy, gonioscopy, ophthalmoscopy, tonometry, tonography according to A.P. Nesterov, also OCT, which was carried out on the device "3D OCT-1" by "Maestro 2".

Optic disc scanning was performed using the Optical Disc scanning protocol. The Optic Nerve Head analysis protocol is applied to this protocol. This program allows to determine the size of the optic nerve head, its excavation, parameters of the neuroretinal rim (NRR, rim volume), the ratio of the dimensions of the excavation and the disc, the average width of the nerve in the disc area and other parameters necessary for the diagnosis of glaucoma.

Statistical processing of the obtained results was performed by using standard methods of variation statistics with the use of Student's t-test to assess the reliability of differences on the Statgraphics software on an Intel computer, PentiumCore 2 Duo model, using MicrosoftExcel software.

Dynamic observation and control examination with OCT was performed before treatment and 6 months later in the course of therapy.

Dynamic observation and control examination with OCT was performed before treatment and 6 months later in the course of therapy.

Results

OCT in patients with POAG stages I, II and III was used to assess the state of average NRR volume, dynamics of average retinal nerve fiber layer thickness (RNFL thickness), average thickness of retinal ganglion cell complex (GCC thickness).

The study revealed a decrease in the thickness of the retina in the macular region (Table 1). The analysis of the findings of the retinal ganglion cell complex showed that in both groups there was a thinning of this layer of varying severity depending on the stage of glaucoma.

An identical topography of ganglion cells (GC) layer was detected in both groups: the minimum thickness of the GCC in the foveal and parafoveal zones (from the temporal side, the gradient of the drop towards decreasing was significantly higher), the maximum thickness of the GCC – in perifovea.

The change in the GCC thickness during scanning with the transition from the parafoveal to the perifoveal and foveal zones was smooth. At the same time, in the upper half of the macula, the GCC thickness was significantly higher than in the inferior temporal and inferior nasal regions.

The dynamics of RNFL in the main group with the inclusion of patients was $82.32 \pm 13.12 \mu\text{m}$. During 6-month observation there were no significant changes – $84.33 \pm 14.12 \mu\text{m}$. In the control group, the RNFL thickness also did not change considerably; before treatment, it was $81.40 \pm 12.16 \mu\text{m}$; after 6 months it became $81.42 \pm 11.10 \mu\text{m}$.

Objective registration of the NRR volume did not show any significant progressive reduction of the rim within 6 months of continuation of treatment. The average volume of the NRR in the main group was $0.09 \pm 0.09 \text{ mm}^3$ before the study, after 6 months of observation it became $0.11 \pm 0.09 \text{ mm}^3$.

In the control group, the NRR volume when included in the study was $0.10 \pm 0.07 \text{ mm}^3$, and by the end of the six months of observation it became $0.10 \pm 0.08 \text{ mm}^3$. As a result of the analysis, no statistically significant changes in the dynamics of NRR were found in the control group.

Analysis of data on the assessment of global loss of volume (GVL) revealed a slight decrease in the GCC thickness in patients in the main group, including the three inner retinal layers that most susceptible to damage in glaucoma, in this group was almost unchanged.

Statistical analysis demonstrated statistically significant stabilization throughout the entire observation period ($76.56 \pm 2.65 \mu\text{m}$ before treatment, at the end of observation $77.99 \pm 2.67 \mu\text{m}$).

In the control group, GCC thickness remarkably decreased during the course of the study ($78.57 \pm 1.98 \mu\text{m}$ before treatment, at the end of observation - $75.65 \pm 2.78 \mu\text{m}$).

CONCLUSION

In this study, structural and functional progression in the control group was accompanied by a decrease in the thickness of the RNFL, GCC and the volume of the NRR. In the main group, these parameters were stable during the observation period or had a positive trend, which indicates the neuroretinoprotective effect of OMK 2.

Including the applications of OMK 2 medications were relatively sensitive GCC parameters, and demonstrated statistically significant stabilization.

Thus, the use of OMK 2 allows improving the functional characteristics in patients with POAG. The positive effect is presumably associated with IOP control and neuroprotective properties of the medicine.

REFERENCES

1. Abulkasimova Kh.Kh., Karimova M.Kh.. Evaluation of the local antihypertensive drugs effect on the status of the morphometric parameters of the optic nerve and macula in patients with primary open-angle glaucoma/ *Sovremenniy tekhnologii v oftalmologii* No. 3 2019 (in Russian). «Fyodorovskiye chteniya» XVI All-Russian scientific and practical conference with international participation, 10-13 pages. doi.org/10.25276/2312-4911-2019-3-10-13
2. Abulkasimova Kh.Kh., Karimova M.Kh., Zakirkhodjayeva M.A. Comparative Analysis Of The Electrophysiological Indicators Of The Optic Nerve In Complex Treatment Of Patients With Primary Open-Angle Glaucoma. *The American Journal of Medical Sciences and*

- Pharmaceutical Research, 2(08), 11-17. (TAJMSPR) SJIF-5.286 DOI-10.37547/TAJMSPR.Volume 2 Issue 8, 2020. ISSN 2689-1026.
3. Abulkasimova Kh.Kh., Karimova M.Kh. Citicoline applications as a complex primary treatment. Uzbek medical journal. №6 2020. DOI <http://dx.doi.org/10.26739/2181-0664-2020-6-3>. 18-22 pages.
 4. Abulkasimova Kh.Kh. Assessment of the effect of nootropic eye drops to peripheral visual field in patients with primary open-angle glaucoma. 38th Congress of the EUROPEAN SOCIETY OF CATARACT & REFRACTIVE SURGEONS. Amsterdam 2020.
 5. Kasimova M.S., Madirimov I.R. Evaluation of the neuroprotective effect of combination therapy in patients with primary open-angle glaucoma (POAG). Stomatologiya No.2 (75) 2019, 64-66 pages.
 6. Bikbov M.M., Babushkin A.E., Orenburkina O.I. Current opportunities for the prevention of excessive scarring after antiglaucoma surgeries using antimetabolites. Natsionalniy zhurnal glaukoma. 2019; 18(3):55-60.
 7. E.A. Egorov, V.P. Elichev, V.V. Strakhov, S.YU. Petrov, T.B. Romanova, M.V. Vasina, V.S. Zinina, A.S. Makarova, S.YU. Kazanova, A.V. Yartsev. Structural and functional changes in the retina of patients with primary open-angle glaucoma and compensated intraocular pressure while undergoing retinoprotective therapy. Vestnik Oftalmologii No.3, 2019, 20-30 pages.
 8. Korelina V.E., Chekurova L.V., Lauta V.F. POSSIBILITIES OF NEUROPROTECTION IN GLAUCOMA. Conference Glaucoma: theory and practice. Horizons of neuroprotection. Collection of scientific articles, St. Petersburg 2014. Issue No. 9, 43-47 pages.
 9. Lavinsky F, Wu M, Schuman JS, et al. Can macula and optic nerve head parameters detect glaucoma progression in eyes with advanced circumpapillary retinal nerve fiber layer damage? Ophthalmology 2018; 125:12:1907.
 10. Petrova K., Anguelov B. Diagnostic accuracy of ganglion cell complex parameters in early, moderate advanced glaucoma // Bulgarian forum glaucoma. 2014. V. 4. № 2. P. 53-58.
 11. Ahmad A. Aref, MD, MBA, Anand Bhatt, Ian Conner, MD, PhD and Samuel Asanad, MD. American Academy of ophthalmology. Neuroprotection in Glaucoma. By Ian Conner, MD, PhD on April 22, 2020.
 12. Banegas SA, Anton A, Morilla A, et al. Evaluation of the retinal NFL thickness, the mean deviation, and the visual field index in progressive glaucoma. J Glaucoma 2016; 25:3:e229-e235.
 13. Gandolfi S, Marchini G, Caporossi A, et al. Cytidine 5'-Diphosphocholine (Citicoline): Evidence for a Neuroprotective Role in Glaucoma. Nutrients. 2020; 12(3).
 14. Kaur IP, Smitha R. Penetration enhancers and ocular bioadhesives: two new avenues for ophthalmic drug delivery. Drug Dev Ind Pharm. 2002 Apr; 28(4):353–69. <https://doi.org/10.1081/ddc-120002997> PMID: 12056529.

15. Kaushik S., Pandav S.S., Ram J. Neuroprotection in glaucoma. *J Postgrad Med* 2003; 49(1):90–95.
16. Lee WJ, Baek SU, Kim YK, et al. Rates of ganglion cell-inner plexiform layer thinning in normal, open-angle glaucoma and pseudoexfoliation glaucoma eyes: A trend-based analysis. *Investig Ophthalmol Vis Sci* 2019;60:2:599-604.
17. Mori S., Hangai M., Nakanishi H., Kotera Y., Inoue R., Morishita S., Aikawa Y., Hirose F., Ojima T. Measurement by spectral domain optical coherence tomography for glaucoma diagnosis N. Yoshimura Kyoto University. Kyoto, Japan. IOVS. 2008. Suppl. 4651 P. 368–375.
18. Roberti G, Tanga L, Parisi V, et al. A preliminary study of the neuroprotective role of citicoline eye drops in glaucomatous optic neuropathy. *Indian J. Ophthalmol.* 2014; 62:549–553.
19. Xu X, Xiao H, Guo X, et al. Diagnostic ability of macular ganglion cell-inner plexiform layer thickness in glaucoma suspects. *Med (United States)* 2017; 96:51:e9182.